



REVIEW ARTICLE

A systematic review of the claw toe deformity: What is known and what is needed apart from surgical procedures

José de Jesús Mayagoitia-Vázquez^{1,2} | Daniel López-López²  |
Israel Miguel-Andrés³  | Ricardo Becerro-de-Bengoa-Vallejo⁴ |
Marta Losa-Iglesias⁵ | Juan Gómez-Salgado^{6,7} | Luis Ángel Ortiz-Lango^{2,3}

¹Biomecánica, Centro de Innovación Aplicada en Tecnologías Competitivas, León, Guanajuato, Mexico

²Research, Health and Podiatry Group, Department of Health Sciences, Faculty of Nursing and Podiatry, Industrial Campus of Ferrol, Universidade da Coruña, Ferrol, Spain

³Laboratorio Nacional CONAHCYT en Biomecánica del Cuerpo Humano., CIATEC, A.C., León, Guanajuato, Mexico

⁴Faculty of Nursing, Physiotherapy and Podiatry, Universidad Complutense de Madrid, Madrid, Spain

⁵Faculty of Health Sciences, Universidad Rey Juan Carlos, Alcorcón, Madrid, Spain

⁶Department of Sociology, Social Work and Public Health, Universidad de Huelva, Huelva, Spain

⁷Safety and Health Postgraduate Programme, Universidad Espíritu Santo, Guayaquil, Ecuador

Correspondence

Daniel López-López, Grupo de Investigación Saúde e Podoloxía, Departamento de Ciencias da Saúde, Facultade de Enfermaria e Podoloxía, Industrial Campus of Ferrol, Universidade da Coruña, Ferrol 15403, Spain.
Email: daniellopez@udc.es

Funding information

Universidade da Coruña/CISUG

Abstract

The claw toe deformity is a painful condition that mainly affects the adult population. Although there are many different treatments to solve the deformity, there is no optimal procedure to restore the normal foot mechanics. The objective of this review was to identify the technical features of the kinematic evaluation methods used in patients with claw toes. Furthermore, the aim of this review was to clarify what is known and what is needed apart from the surgical procedures to correct the claw toe deformity, with the purpose of reducing risk factors of falling in elderly people. A search in electronic databases, such as Scopus ($n = 78$), Google Scholar ($n = 705$) and ScienceDirect ($n = 290$) was conducted. There were seven articles (43.75%) related to the fixation (arthrodesis) of proximal and distal interphalangeal joints, one article (6.25%) describes the correction of the claw toe through plantar plate tenodesis and release of collateral ligaments, four articles (25%) describe the procedure of tendon transfer, one article (6.25%) describes flexor digitorum brevis tenotomy and a proximal interphalangeal joint arthrolysis, and another article (6.25%) presented the impact of partial phalanx osteotomy to treat the claw toe deformity. In conclusion, the review indicates that there are several studies related to the treatment or correction of claw toe deformity. However, there is a lack of knowledge of the postsurgical effects of treating claw toe condition, especially in the structural mechanics (plantar pressure distribution, stability, gait, foot mechanics

This is an open access article under the terms of the [Creative Commons Attribution-NonCommercial-NoDerivs](https://creativecommons.org/licenses/by-nc-nd/4.0/) License, which permits use and distribution in any medium, provided the original work is properly cited, the use is non-commercial and no modifications or adaptations are made.

© 2024 The Author(s). *International Wound Journal* published by Medicalhelplines.com Inc and John Wiley & Sons Ltd.

and so on) of the foot after the correction of the claw toe deformity. The analysis of the foot mechanics after the correction of the claw toes has to be paramount to determine the benefits of the correction.

KEYWORDS

claw toes, foot, gait, lesser toes deformities

Key Messages

- We have evaluated the technical features of the kinematic evaluation methods used in patients with claw toes.
- There is a lack of knowledge of the postsurgical effects to treat claw toe pathology.
- The increase of outcomes knowledge of claw toe deformity in foot surgery are extremely important to control foot health.

1 | INTRODUCTION

The increase in life expectancy is directly related to the increase in the population of elderly people. Elderly people are more prone to suffer from musculoskeletal disorders of the foot, where claw toe is one of the most common pathologies.¹⁻⁴ This deformity affects more frequently to women than men.^{2,5} Several studies have been performed to elucidate the claw toe deformity.^{2,6-9} At the beginning, the claw toe condition was not well defined and produced confusion with other lesser toe deformities, such as hammer toes or mallet toes. Nowadays, it is clearly explained and easy to identify.^{10,11} The claw toe is a musculoskeletal disorder of the foot where the metatarsophalangeal joint (MTPJ) is hyperextended and the proximal and distal phalangeal joints are flexed.^{6,8} On the other hand, hammer toes present a similar condition to claw toes, the only difference is the extension or dorsiflexion of the distal interphalangeal joint (DIPJ). Mallet toes are in a similar condition as well, in this case, the MTPJ and proximal interphalangeal joint (PIPJ) stay neutral or straight and the DIPJ remains flexed. In summary, the difference between these conditions is the rotation of the MTPJ and DIPJ.

The claw toe is a painful condition presented with more frequency in the second toe, usually, the pain is produced due to the friction between the interphalangeal joints and the internal surface of the shoes. After a period of time, this friction can produce ulcers or calluses. These alterations appear in the dorsal part of the toes and at the tip of the toe.

Nowadays, it is known that this deformity of the foot is produced by different factors, such as congenital deformity, inflammatory arthropathies, neuromuscular conditions, hallux valgus, cavus foot, wearing high-heeled shoes, muscle imbalance, ill-fitting footwear and excessively long metatarsals.^{2,5,7} Although there are several

causes that produce claw toes, the neurological diseases are the most common causes.¹²

Although there are several surgical procedures to correct the claw toe deformity, there is a lack of information about the effect of this deformity on the gait biomechanics, plantar pressure distribution and loss of balance.¹ In addition, although the surgery solves the malformation and reduces the pain, there is no clear evidence of the effects after the surgical procedures to correct the claw toe pathology. Moreover, it is something that needs to be carefully considered, as some surgeons suggest that conservative treatments have to be applied before the surgical procedure. In most cases, the surgical procedure is selected when the malformation produces pain and discomfort in the patients, and it should not be chosen just for cosmetic reasons.^{2,13}

It is known that most musculoskeletal disorders of the foot, such as flat feet, cavus foot, claw toes, hammer toes and hallux valgus, will have a negative effect on the biomechanics of the lower limbs or other parts of the body structure. In some cases, these pathologies could produce pain, transfer lesions, callus formation and gait changes. The lesser toes play an important role in the stability and balance of the foot during static or dynamic conditions.⁷ The toes of the foot contribute to the push-off phase as they are the last part of the foot in contact with the ground during the stance phase. Therefore, it is paramount to study any malformation of the lesser toes that can affect the natural behaviour of the foot. Although several surgical procedures have been developed to correct the claw toe deformity, none surgical procedures completely solve the condition.^{7,14-16} This means that the natural physiology of the foot during gait kinematics will not be completely recovered.

The claw toe is a malformation of the foot mainly presented in the second toe, although it can be presented

also in the other toes. This deformity can produce an emotional negative impact as the normal anatomy of the foot is modified. Moreover, this foot condition has an important impact in the quality of life of patients, as it produces pain, callous, tissue wounds and gait affections. The surgical treatment of this foot condition is one of the most performed by surgeons, being an economical impact for patients.^{6,7,11,12,16}

Therefore, the objective of this systematic review is to identify the technical features of the kinematic evaluation methods used in patients with claw toes. Furthermore, the aim of this review is to clarify what is known and what is needed apart from the surgical procedures to correct the claw toe deformity, with the purpose of reducing risk factors of falling in elderly people. It was hypothesized that the surgical correction of the claw toe condition does not completely solve the mechanics of the foot, and further studies have to be done to evaluate the consequences of keeping the toes in straight position.

2 | METHODS

2.1 | Study design

The review protocol was registered with the record number CRD42023473207 in the International Prospective Register of Systematic Reviews. The systematic review was conducted in accordance with the Preferred Reporting Items for Systematic Reviews and Meta-Analyses statement.¹⁷

2.2 | Search strategy

The systematic review was conducted in electronic databases, such as Scopus ($n = 78$), Google Scholar ($n = 705$) and ScienceDirect ($n = 290$). The following search equation was used in English and Spanish in the three databases: 'Claw Toes' AND 'treatment' AND 'Stability'. The inclusion criteria considered articles that have the three words of the search equation and that they were published from 2010 up to February 2023. The search equation gave a total of 1073 studies. After reviewing the articles, conference proceedings, duplicated manuscripts, books, theses and studies from a different language to English or Spanish were excluded from the analysis, having a final number of 16 articles. Figure 1 shows the flow diagram for the review. The revision of the articles was done independently by two authors considering the inclusion and exclusion criteria.

After reviewing the three databases, 132 duplicated manuscripts were removed. Then, a revision of the title,

summary and the three keywords in the article was performed. After screening the articles, 879 articles were excluded. Then, a deeper analysis was performed in the 62 manuscripts retrieved. Those articles were reviewed in detail having in mind the scope of the review. At the end and by agreement between the authors, 16 manuscripts were included in the review.

2.3 | Synthesis of information and management of search results

Two expert reviewers revised the search findings related to the conservative and surgical procedures to correct the claw toe deformity. If doubts appear during the data extraction, the whole research group participated to have an agreement. All references to add were manually evaluated, and those manuscripts that might be incorporated were also reviewed and obtained. We retrieved information related to all articles resulting from the Preferred Reporting Items for Systematic Reviews and Meta-Analyses declaration, using a standardized format that is shown in Table 1. We showed information from every research in an evidence table with information qualitative, and a global conclusion has been realized. The level of risk of bias assessment in the systematic review was done using the Review Manager (RevMan) software of the Cochrane Library, v.5.5. It has not been possible to perform a meta-analysis because of the principal heterogeneity of the incorporated studies.

3 | RESULTS

The claw toe is a common deformity of the foot that produces pain and discomfort. It should not be considered a minor problem as this condition could affect the stability of the person or affect the gait pattern.^{7,18} Several studies have been developed to correct the claw toe deformity. However, there is no general consensus on the optimal treatment of correction. First, it is important to understand the aetiology or the causes that produce the deformity of the claw toes. This is important to choose the best treatment and succeed in the correction of the condition. Several surgical treatments have been developed to correct the deformity, such as arthrodesis of the proximal and DIPJ, tendon transfer, tenotomies, fixation of the MTPJ, arthroplasty, soft-tissue capsulotomy, tendon release (Stainsby procedure), silicone implants and amputation.^{7,18,19} Second, it is also important to know that there are other nonsurgical treatments that have to be considered before choosing the surgical ones. These conservative or nonsurgical treatments involve the use of

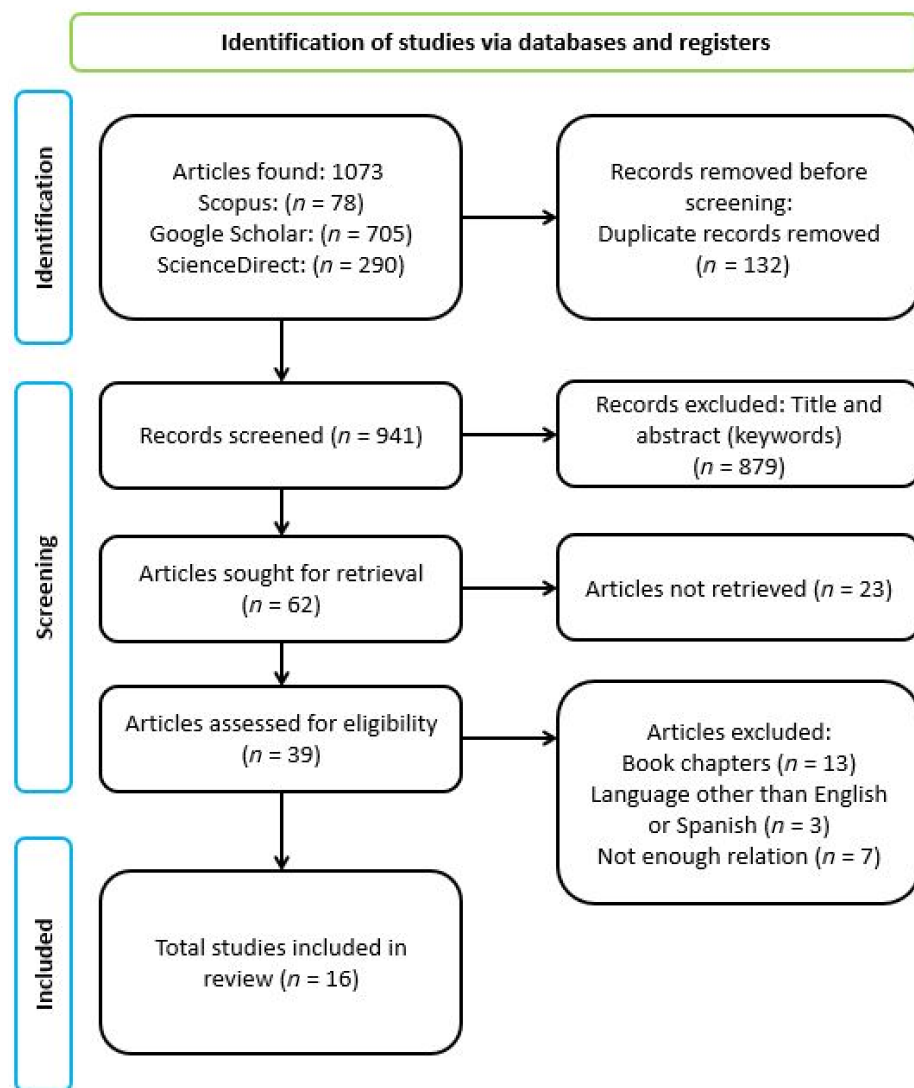


FIGURE 1 Preferred Reporting Items for Systematic Reviews and Meta-Analyses 2020 flow diagram for the systematic review.

silicone gel pads, taping or strapping the affected toe, shoes with wide toe boxes and injection of botulinum toxin.^{7,20} The conservative treatments should be preferred over the surgical ones.

The aim of this review was to understand the treatments to correct the claw toe pathology and the consequences after applying the treatments. This means, what is known and what is needed to understand the effects of the claw toe pathology before and after the surgical procedure of correction. It is known that the claw toe deformity can be corrected but there is still lack of knowledge about the physiology of the foot mechanics after the correction. There is no information that reports the kinematic effect of the surgical intervention to correct the claw toe deformity. It is known that the lesser toe deformities such as, the claw toes or hammer toes, could affect the stability of the persons,⁷ but nobody reports the kinematics parameters or stability after the surgery.

Although different studies have been performed with Finite Element to identify the effect of the surgical procedure to correct the claw toe, additional research is needed to identify the loss of balance or instability in the patients.^{14,21,22}

After screening 1073 articles, we selected 16 studies related to the treatments of the claw toes; see Table 1. There were seven articles (43.75%) related to the fixation (arthrodesis) of proximal and DIPJ,^{7,13,23–27} one article (6.25%) that describes the correction of the claw toe through plantar plate tenodesis and release of collateral ligaments,²⁸ four articles (25%) describe the procedure of tendon transfer,^{12,19,29,30} one article (6.25%) describes flexor digitorum brevis tenotomy and a PIPJ arthrolysis³¹ and other article (6.25%) presents the impact of partial phalanx osteotomy to treat the claw toe deformity.³² Furthermore, one article (6.25%) analysed the anatomy of the deformity, pathophysiology, causes of the claw toe pathology, treatments and classification of the

TABLE 1 Systematic review of the claw toe deformity.

Author	Treatment	Deformity resolved	Limitations	Kinematic evaluation	Stability	Conclusions
Ellington et al. ²³	Interphalangeal joint arthrodesis, StayFuse™ device	Claw toe, hammer toe	Joint instability or deformity in some patients, including hyperextension deformity. Not using exposed instrumentation. Costly. Only includes radiographic outcomes	No	No	Procedure is efficacious in maintaining PIP alignment with a relatively low reoperation rate
Stolwijk et al. ³³	MTPJ and PIPJ resection	Claw toe	Plantar pressure redistribution. Decrement of pressure at distal area and increment of pressure at proximal area	Yes	Yes	Plantar pressure under the metatarsal heads transfers after correction of the claw toes with repositioning of the MTPJ and the plantar soft tissues
Payo-Ollero et al. ²⁴	Nitinol intramedullary implant for arthrodesis	Claw toe, hammer toe	Correction of the deformity. High arthrodesis rate after mean of 2.4 years. It can develop mallet toe afterwards	No	No	Implants are a good option to reduce deformity in the PIPJ in claw toe or hammertoe deformities
Wei et al. ²⁵	Ideal intramedullary implant for arthrodesis	Claw toe, hammer toe	The devices work well, but do not present advantages in pain level, satisfaction, foot-related function or surgical complication compared with K-wires	No	No	Novel internal devices may outperform K-wires in union rate for PIPJ arthrodesis. They seem not to present advantages in clinical parameters
Leung and Lui ²⁸	Plantar plate tenodesis	Claw toe	Complete soft-tissue balance around the MTPJ. Procedure is technically demanding. Risks on articular cartilage damage, interdigital nerve damage, digital arteries damage, deformities and toe stiffness	No	No	EDL tenotomy can be performed and all the pulling force of EDL will be transmitted planarly to stabilize the plantar plate
Cosín-Matamoros et al. ²⁹	FDB tendon intramedullary transfer	Claw tow, hammer toe	Absence of fracture force evaluation and force produced in the phalanx in FDB tendons	No	No	Tendons of the second, third and fourth toes can perform tendon transfer
Averous et al. ²⁶	Radiolucent intramedullary implant for arthrodesis	Claw toe, hammer toe	No infections or implant breaks. Offers immediate mechanic stability, deformity correction and high rate of consolidation	No	No	PIPJ arthrodesis is a good solution. Implant used offers good immediate benefits and no short-term or long-term tolerance issues. Toe grip device
Errichiello et al. ¹²	Brevis and longus tendon transfer	Claw toe	Preferable to use FDB tendon above FDL tendon. FDL tendon generates loss of stability on DIPJ and released tension of the central extensor band	No	No	FDL transfer does not dynamically correct the claw toe at the PIP joint and it causes loss of the stabilizing action of the DIP
Klammer et al. ²⁷	Arthrodesis, K-wire transfixion	Claw toe, hammer toe	Once arthrodesis is performed, a minimum period of 6 weeks of use of the K-wire is needed to reduce the probability of malalignment problems	No	No	Higher rate of malalignment after 3 weeks as compared with 6 weeks Kirschner wire transfixion. Longer transfixion times of 6 weeks did not lead to an increase in K-wire associated complication rates

(Continues)

TABLE 1 (Continued)

Author	Treatment	Deformity resolved	Limitations	Kinematic evaluation	Stability	Conclusions
Concannon et al. ¹⁹	Stainsby procedure	Claw toe	There was no subsequent review. There was no comprehensive comparison with previous results	No	No	This modification of Stainsby procedure is a safe, fast and effective procedure for the correction of claw toe deformity
Matthews et al. ³⁰	Cobb–Stainsby arthroplasty	Claw toe, hammer toe	Infection in a certain number of patients. The deformity continued in some patients. The data are subjective	No	No	Favourable results and addressing of concerns about high patient satisfaction. It does not use K-wire to stabilize the toe
Ellington ⁷	Arthroplasty, arthrodesis	Claw toe, hammer toe	Complications include swelling, numbness, pain, stiffness, malalignment or loss of the toe due to vascular insult	No	No	The best surgical correction and fixation techniques are still to be determined. Each patient much be evaluated thoroughly, and treatment should be tailored
Sergio Fernández et al. ¹³	Non-surgical and surgical (arthrodesis and arthroplasty) treatment	Claw toe	Level of satisfaction varies depending on technique. Possible infection. Different types of devices for technique	No	No	All three methods described work well at fixing the deformity. Vague conclusion overall about technique outcomes
Carvalho et al. ³¹	FDB tenotomy and PIPJ arthrolysis	Claw toe	Inconsistent section of FDB slips, possibly causing loss of stability at walk. Only cadaveric study	No	No	Correction of the deformity was achieved in all cases but with an inconsistent section of FDB slips
Darcel and Piclet-Legré ¹⁸	Multiple operative approaches	Claw toe, hammer toe, mallet toe	Lists a variety of treatments with multiple decision trees, but with little depth. Does not conclude nor discusses the subject	No	No	Most treatments of claw toe can be done based of decision trees presented. Surgical procedures must be done in order from MTP, DIPJ and PIPJ respectfully
Nieto-García et al. ³²	Partial or incomplete osteotomy	Claw toe, hammer toe, hallux valgus	Hammer toe and claw toe were not considered clinically different. Does not develop further in long-term outcomes	No	No	Should be considered using osteotomies as an alternative surgery for the treatment of lesser toe deformities. Procedure gives functional and biomechanical restoration, and a low percentage of complications. In addition to tenotomies enhances the occurrence of adverse events

Abbreviations: DIPJ, distal interphalangeal joint; EDL, extensor digitorum longus; FDB, flexor digitorum brevis; FDL, flexor digitorum longus; MTPJ, metatarsophalangeal joint; PIPJ, proximal interphalangeal joint.

deformity.¹⁸ Finally, there was just one article (6.25%) that study the foot kinematics and the plantar pressure after the correction of the claw toe deformity with the release of the MTPJ.³³

Finally, the risk of bias was evaluated in these 16 articles. Fifteen articles did not specify the blinding of outcome assessment and just one manuscript mentioned. The studies of Ellington 2011 and Nieto-García 2019 did not specify or were not applicable to the risk of bias criteria. Most of the studies involved surgical procedures and, in some cases, evaluating the risk of bias was not possible or the information was not clear. All data are shown in Figures 2 and 3.

4 | DISCUSSION

Lesser toe deformities, such as claw toes are a common complaint in the adult population. This foot deformity is a painful condition with a significant impact on the quality of life of the patients.^{7,18,23} Although several techniques to correct the claw toe condition have been described, there is still no optimal treatment to fully correct the deformity.^{7,24} Conservative treatments are the first approach to solving the foot condition, but if these do not correct the deformity a surgical procedure is applied. The fixation (arthrodesis) of the interphalangeal joints was habitually done with K-wires.²⁷ They were considered the gold standard method for the fixation of the interphalangeal joints. However, although this was done for a long period of time, this procedure sometimes produces complications, such as discomfort, infection, rotation of phalanges or breakage of the wires.²⁶ Nowadays, new intramedullary implants have been developed, and they are less invasive and produce less complications.^{23–26}

In this review, we found seven articles related to the fixation of the interphalangeal joints.^{7,13,23–27} Ellington describes different techniques to correct the claw toe deformity, conservative and surgical ones. He concluded

that it is important to understand the causes of the deformity to apply the treatment. Furthermore, he prefers arthrodesis of the PIPJ through an intramedullary device to correct the claw toes.^{7,13} Other authors have described the fixation of the MTPJ, PIPJ and DIPJ through an intramedullary nitinol implant (Smart-Toe[®]). This procedure helps to correct the claw toe deformity.²⁴ In a study, 36 patients with lesser toe deformities were treated with this intramedullary implant. The results showed that the implant is a good option to treat lesser toe deformities.²⁴ However, in some cases, this type of implant can produce problems of fixation of the joint or infections.

The stiffness produced by the fusion of the medial and distal joints can cause discomfort or pain in the fingers.¹³ Although Sergio Fernández et al.¹³ reported that patients prefer a stiff but straight toe, it is important to understand the consequences or effects on the foot mechanics. The stiffness of the joints keeps a fixed position (without flexion or extension) of the toes and a permanent contact with the shoe that over time can cause pain or fracture of the wire or screw implant.

Other surgical techniques (tendon transfer) have been developed to reduce the stiffness of the phalangeal joints and correct the claw toe deformity. However, the flexor digitorum longus and flexor digitorum brevis tendon transfer does not completely resolve the foot condition. In some cases, this treatment could produce a loss of stability in the phalanges structure.^{12,19,29,30}

Lesser toe deformities are a risk factor for falls in elderly people.^{2,18} Claw toes deformity can be rigid or flexible. Most of the times, this deformity is rigid and can be corrected with a surgical procedure. It is believed that the hyperextension of the MTPJ could increase the plantar pressure in the metatarsal region of the foot, and this may result in a metatarsalgia.⁷ We just found one article that measures the plantar pressure distribution and foot kinematics before and after surgical correction of the claw toe deformity. Although there was a better distribution of the plantar pressure of the foot after the surgery, the authors commented that more quality studies will be

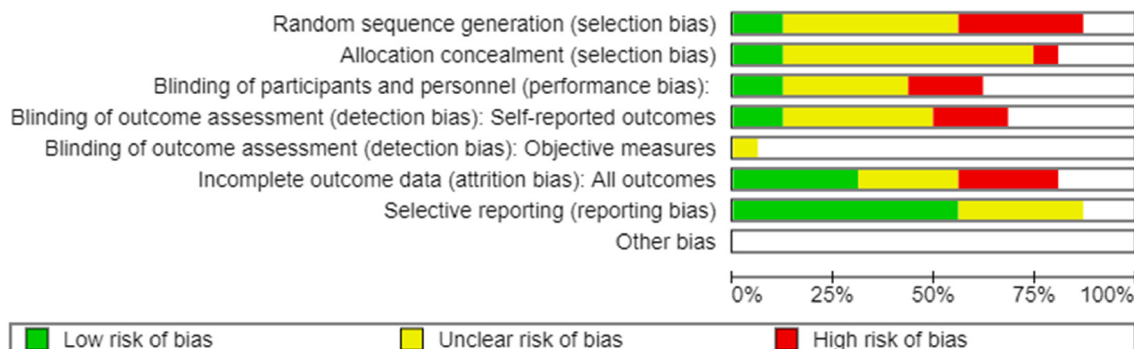


FIGURE 2 Analysis of the risk of bias of the studies included. (1) Green (low risk), (2) yellow (unclear risk) and (3) red (high risk).

	Random sequence generation (selection bias)	Allocation concealment (selection bias)	Blinding of participants and personnel (performance bias)	Blinding of outcome assessment (detection bias)	Self-reported outcomes	Blinding of outcome assessment (detection bias)	Objective measures	Incomplete outcome data (attrition bias)	All outcomes	Selective reporting (reporting bias)	Other bias
Averous 2015	?	?	-	-					-	+	
Carvalho 2021	?	?							?	?	
Concannon 2014	?	?	-	-					?	?	
Cosin-Matamoros 2020	-	+	+	+					+	+	
Darcel 2023	+	+								+	
Ellington 2010	?			?					+	+	
Ellington 2011									?	?	
Errichiello 2012	?	?	?	?					-	+	
Fernández 2012	?	?	?	?	?				?	?	
Klammer 2012	+	?	?	-					+	+	
Leung 2022	?	?									
Matthews 2016	-	?	-	?					+	+	
Nieto-García 2019											
Payo-Ollero 2019	-	?	?	?					-	+	
Stolwijk 2019	-	-	+	+					+	+	
Wei 2020	-	?	?	?					-	?	

FIGURE 3 Risk of bias summary in the studies. (1) Green (low risk), (2) yellow (unclear risk) and (3) red (high risk).

needed to support the idea.³³ This was a less invasive surgical treatment to correct the claw toe deformity.³³ The surgical technique consists in releasing the MTPJ, repositioning of the plantar fat pad and resection of the PIPJ. The plantar pressure distribution was measured 3 months before and 12 months after the surgery. The

results of the study after the surgery demonstrated that the plantar pressure distribution was modified, providing a more equal plantar pressure distribution.³³

After reviewing 16 articles, we have discovered that the claw toe deformity remains a problem for patients, although they have been treated with a surgical procedure. Then our hypothesis has been proven.

The results of this review indicate that future work needs to be done in patients with and without claw toe deformity to analyse the foot mechanics and the plantar pressure distribution in static and dynamic conditions. This with the purpose of clarifying the effect on the gait kinematics and plantar pressure distribution. Furthermore, a deeper analysis needs to be performed to identify if the claw toe deformity produces a significant effect in the loss of balance. This is important due to the fact that the foot condition is more recurrent in elderly people and the stability in this population is imperative to avoid falls. The correction (conservative or surgical treatment) of the claw toe deformity should have a minimal impact on the natural behaviour of the lesser toes and the foot mechanics.

5 | CONCLUSION

In conclusion, the systematic review indicates that there are several studies related to the treatment or correction of claw toe deformity. However, there is a lack of knowledge of the postsurgical effects to treat claw toe condition, especially in the structural mechanics (Plantar pressure distribution, stability, gait, foot mechanics and so on) of the foot after the correction of the claw toe deformity. The analysis of the foot mechanics after the correction of the claw toes has to be paramount to determine the benefits of the correction.

ACKNOWLEDGEMENTS

Funding for open access charge: Universidade da Coruña/CISUG.

CONFLICT OF INTEREST STATEMENT

The authors have no conflicts of interest to declare.

DATA AVAILABILITY STATEMENT

The dataset supporting the conclusions of this article is available in the j.mayagoitia@udc.es in the Research, Health and Podiatry Group, Department of Health Sciences, Faculty of Nursing and Podiatry, Industrial Campus of Ferrol, Universidade da Coruña, Spain.

ORCID

Daniel López-López  <https://orcid.org/0000-0002-9818-6290>

Israel Miguel-Andrés  <https://orcid.org/0000-0002-9433-7864>

REFERENCES

- Martínez-Gallardo Prieto L, Hermida Galindo LF, D'hyver de Las Deses C. Prevalencia de patología del pie en una población geriátrica y su impacto en la función, la marcha y el síndrome de caídas. *Rev Esp Geriatr Gerontol*. 2012;47:19-22. doi:10.1016/j.regg.2011.05.004
- Angirasa AK, Augoyard M, Coughlin MJ, Fridman R, Ruch J, Weil L. Hammer toe, mallet toe, and claw toe. *Foot Ankle Spec*. 2011;4:182-187. doi:10.1177/1938640011409010
- Menz HB, Lord SR. The contribution of foot problems to mobility impairment and falls in community-dwelling older people. *J Am Geriatr Soc*. 2001;49:1651-1656. doi:10.1111/j.1532-5415.2001.49275.x
- Muchna A, Najafi B, Wendel CS, Schwenk M, Armstrong DG, Mohler J. Foot problems in older adults: associations with incident falls, frailty syndrome, and sensor-derived gait, balance, and physical activity measures. *J Am Podiatr Med Assoc*. 2018;108:126-139. doi:10.7547/15-186
- García FP, Gutiérrez JO, Jiménez LRB, Nucamendi MAF. Tratamiento de la deformidad en garra de los dedos menores del pie. *Acta Ortopédica Mex*. 2008;22:189-194.
- Schrier JCM, Verheyen CCPM, Louwerens JW. Definitions of hammer toe and claw toe. An evaluation of the literature. *J Am Podiatr Med Assoc*. 2009;99:194-197. doi:10.7547/0980194
- Ellington JK. Hammertoes and clawtoes: proximal interphalangeal joint correction. *Foot Ankle Clin*. 2011;16:547-558. doi:10.1016/j.fcl.2011.08.010
- Myerson MS, Shereff MJ. The pathological anatomy of claw and hammer toes. *J Bone Jt Surgery Inc*. 1989;71-A:45-49.
- Ridley LJ, Han J, Ridley WE, Xiang H. Claw toe. *J Med Imaging Radiat Oncol*. 2018;62:126. doi:10.1111/1754-9485.07_12786
- Simon A. Surgical treatment of hammer toe, claw toe, and mallet toe deformity. In: Saxena A, ed. *International Advances in Foot and Ankle Surgery*. Springer-Verlag London; 2012:107-124.
- Weyandt Z, Capuzzi M, McGlone W, Bernatsky A, Ford T. Lesser toe deformity classification: a simplified approach with treatment influence. *Foot*. 2021;48:101819. doi:10.1016/j.foot.2021.101819
- Errichiello C, Marcarelli M, Pisani PC, Parino E. Treatment of dynamic claw toe deformity flexor digitorum brevis tendon transfer to interosseous and lumbrical muscles: a literature survey. *Foot Ankle Surg*. 2012;18:229-232. doi:10.1016/j.fas.2012.04.005
- Sergio Fernández C, Wagner E, Ortiz C. Lesser toes proximal interphalangeal joint fusion in rigid claw toes. *Foot Ankle Clin*. 2012;17:473-480. doi:10.1016/j.fcl.2012.07.004
- Bayod J, Losa-Iglesias M, De Bengoa-Vallejo RB, Prados-Frutos JC, Jules KT, Doblaré M. Advantages and drawbacks of proximal interphalangeal joint fusion versus flexor tendon transfer in the correction of hammer and claw toe deformity. A Finite-Element study. *J Biomech Eng*. 2010;132:51002. doi:10.1115/1.4001115
- Hedegaard Andersen J, Rasmussen A, Frimodt-Møller M, Rossing P, Kirketerp-Møller K, Engberg S. The effect of needle tenotomy on hammer, mallet and claw toe deformities in patients with diabetes, a retrospective study. *J Clin Transl Endocrinol*. 2019;18:100208. doi:10.1016/j.jcte.2019.100208
- Brandão RA, Larson D. Hammertoes and claw toes: primary and revision. In: Hyer CF, Berlet GC, Philbin TM, Bull PE, Prissel MA, eds. *Essential Foot and Ankle Surgical Techniques: A Multidisciplinary Approach*. Springer International Publishing; 2019:51-56. doi:10.1007/978-3-030-14778-5_5
- Page MJ, McKenzie JE, Bossuyt PM, et al. The PRISMA 2020 statement: an updated guideline for reporting systematic reviews. *BMJ*. 2021;372:n71. doi:10.1136/bmj.n71
- Darcel V, Piclet-Legré B. Lesser-toe deformity. *Orthop Traumatol Surg Res*. 2023;109:103464. doi:10.1016/j.otsr.2022.103464
- Concannon E, MacNiocaill R, Flavin R, Kearns S. A novel modification of the Stainsby procedure: surgical technique and clinical outcome. *Foot Ankle Surg*. 2014;20:262-267. doi:10.1016/j.fas.2014.06.006
- Takekawa T, Takagi S, Kitajima T, Sato T, Kinoshita K, Abo M. Claw toe: anatomic guide for injection of botulinum toxin into foot muscles. *Can J Neurol Sci*. 2022;49:102-108. doi:10.1017/cjn.2021.52
- García-González A, Bayod J, Prados-Frutos JC, et al. Finite-element simulation of flexor digitorum longus or flexor digitorum brevis tendon transfer for the treatment of claw toe deformity. *J Biomech*. 2009;42:1697-1704. doi:10.1016/j.jbiomech.2009.04.031
- Bayod J, de Bengoa Vallejo RB, Losa Iglesias ME, Doblaré M. Stress at the second metatarsal bone after correction of hammertoe and claw toe deformity: a finite element analysis using an anatomical model. *J Am Podiatr Med Assoc*. 2013;103:260-273. doi:10.7547/1030260
- Ellington JK, Anderson RB, Davis WH, Cohen BE, Jones CP. Radiographic analysis of proximal interphalangeal joint arthrodesis with an intramedullary fusion device for lesser toe deformities. *Foot Ankle Int*. 2010;31:372-376. doi:10.3113/FAI.2010.0372
- Payo-Ollero J, Casajús-Ortega A, Llombart-Blanco R, Villas C, Alfonso M. The efficacy of an intramedullary nitinol implant in the correction of claw toe or hammertoe deformities. *Arch Orthop Trauma Surg*. 2019;139:1681-1690. doi:10.1007/s00402-019-03203-w
- Wei RXY, Ling SKK, Lui TH, Yung PSH. Ideal implant choice for proximal interphalangeal joint arthrodesis in hammer toe/-claw toe deformity correction: a systematic review. *J Orthop Surg*. 2020;28:1-9. doi:10.1177/2309499020911168
- Averous C, Leider F, Rocher H, et al. Interphalangeal arthrodesis of the toe with a new radiolucent intramedullary implant (Toegrip). *Foot Ankle Spec*. 2015;8:520-524. doi:10.1177/1938640015599031
- Klammer G, Baumann G, Moor BK, Farshad M, Espinosa N. Early complications and recurrence rates after kirschner wire transfixion in lesser toe surgery: a prospective randomized study. *Foot Ankle Int*. 2012;33:105-112. doi:10.3113/FAI.2012.0105
- Leung YT, Lui TH. Claw toe with dislocated second metatarsophalangeal joint: treated by plantar plate tenodesis and release of collateral ligaments. *Arthrosc Tech*. 2022;11:e1695-e1702. doi:10.1016/j.eats.2022.06.002
- Cosin-Matamoros J, Becerro-de-Bengoa-Vallejo R, Losa-Iglesias ME, et al. Intramedullary transfer of the flexor digitorum

- brevis tendon for the correction of clawtoe/hammertoe deformity: a cross-sectional study. *Ann Anat.* 2021;234:151646. doi:[10.1016/j.aanat.2020.151646](https://doi.org/10.1016/j.aanat.2020.151646)
30. Matthews AH, Jagodzinski NA, Westwood M, Metcalfe JE, Trimble KT. Effectiveness of the Cobb–Stainsby excision arthroplasty. *Foot Ankle Surg.* 2018;24:49–53. doi:[10.1016/j.fas.2016.11.007](https://doi.org/10.1016/j.fas.2016.11.007)
31. Carvalho P, Dalmau-Pastor M, Lozi C, Souza M, Lucas-Y-Hernandez J, Laffenêtre O. Percutaneous flexor digitorum brevis tenotomy: an anatomical study. *Foot Ankle Surg.* 2022;28:176–180. doi:[10.1016/j.fas.2021.02.011](https://doi.org/10.1016/j.fas.2021.02.011)
32. Nieto-García E, Ferrer-Torregrosa J, Ramírez-Andrés L, Nieto-González E, Martínez-Nova A, Barrios C. The impact of associated tenotomies on the outcome of incomplete phalangeal osteotomies for lesser toe deformities. *J Orthop Surg Res.* 2019;14:1–10. doi:[10.1186/s13018-019-1353-0](https://doi.org/10.1186/s13018-019-1353-0)
33. Stolwijk NM, Keijsers NLW, Pasma JH, Nanhoe-Mahabier W, Duysens J, Louwerens JWK. Treatment of metatarsalgia based on claw toe deformity through soft tissue release of the metatarsophalangeal joint and resection of the proximal interphalangeal joint: evaluation based on foot kinematics and plantar pressure distribution. *Foot Ankle Surg.* 2020;26:755–762. doi:[10.1016/j.fas.2019.09.003](https://doi.org/10.1016/j.fas.2019.09.003)

How to cite this article: de Jesús Mayagoitia-Vázquez J, López-López D, Miguel-Andrés I, et al. A systematic review of the claw toe deformity: What is known and what is needed apart from surgical procedures. *Int Wound J.* 2024;21(10):e70073. doi:[10.1111/iwj.70073](https://doi.org/10.1111/iwj.70073)